

JOSEPH A. JACHIMCZYK, M.D., J.D.

FORENSIC PATHOLOGIST

ATTORNEY AT LAW

CHIEF MEDICAL EXAMINER



228-8311

EXT. 671 (DAY)

EXT. 212 (NIGHT)

OFFICE OF THE MEDICAL EXAMINER
OF HARRIS COUNTY

HARRIS COUNTY COURT HOUSE
HOUSTON, TEXAS 77002

AUTOPSY REPORT

CASE 73 - 3350

August 12, 1973

PATHOLOGICAL DIAGNOSES ON THE BODY

OF


UNKNOWN #12

1. Gunshot wound of head.
2. Asphyxia due to gagging.

OPINION

It is our opinion that the decedent, Unknown #12, came to his death as a result of gunshot wound of head, in association with sexual mutilation (penectomy and castration), Homicide.

COMMENT: The identity of this decedent is undetermined as of May 9, 1974. The investigation is continuing on a day to day basis. This report, therefore, is not final.



Joseph A. Jachimczyk, M.D., J.D.
Chief Medical Examiner

(SEE COMPANION CASES 73-3332, 73-3333, 73-3334, 73-3335, 73-3336, 73-3337, 73-3338, 73-3339, 73-3347, 73-3348, 73-3349, 73-3353, 73-3354, 73-3355, 73-3356, 73-3357).

POSTMORTEM EXAMINATION ON THE BODY OF

UNKNOWN #12

HISTORY: This body was one of seventeen bodies or skeletal remains recovered from Stall #11 at 4500 Silverbell Street, Houston, Texas, between 6:00 p.m. on August 8, 1973, and 8:00 p.m. on August 9, 1973. (See Companion Cases 73-3332, 73-3333, 73-3334, 73-3335, 73-3336, 73-3337, 73-3338, 73-3339, 73-3347, 73-3348, 73-3349, 73-3353, 73-3354, 73-3355, 73-3356, 73-3357).

AUTOPSY: The autopsy was performed by Chief Medical Examiner Joseph A. Jachimczyk, M.D., assisted by Dr. Paul G. Stimson, beginning at 11:30 a.m. on August 12, 1973, in the Harris County Morgue.

EXTERNAL APPEARANCE: The remains were submitted in a plastic sack and weighed a total of 43 pounds. They consisted of a deteriorating head with dark hair, measuring up to 5-1/2 inches in length and mostly bones and some cheesy-like material with very little soft tissue. There was a strand of parachute-type cord tied about the back sides of the decomposed hands. A faint outline of the soft tissues of the right hand were still discernible, although the tissue was like cheese. Similar cord was tied around the tibias. It appeared that the hands and legs were tied together, posteriorly. There was a small portion of black plastic material present with the remains. Over the head, there was a ligature mark depression at the level of the eyes. There was a terrycloth-type gag in the area of the mouth with adhesive tape around it. The facial tissues were not recognizable. There was a braided leather bracelet about the right wrist, consisting of three strands of leather braided and formed into a small knot at one end. There were no markings on it.

Elsewhere among the remnants, there was a plastic baggie with a knot on one end within which there was another plastic baggie in which there was a decomposing circumcised penis with some attached pubic hair at one end. The penis measured 10 centimeters in overall length. Within each of the other baggies, there was a collapsed testicle, one measuring up to 4-1/2 and the other up to 5 centimeters in greatest dimension.

The skull had some adherent cheesy unrecognizable soft tissue with attached hairs and two sunken cheesy eyeballs within the orbits. The skull was of adult stature, a Caucasian male. The ectocranial suture lines showed no evidence of fusion. The three segments of the hyoid bone were present. The tip of the left cornu was blackened. There was a gunshot hole in the calvarium in the left parietal bone at a point 5 inches above the left auditory meatus. This wound opening measured .25 inches in diameter. The bone edges

were beveled inwardly. The wound admitted a probe which communicated to the 2nd cervical vertebra on the right, where a .22 caliber bullet was recovered in the 2nd cervical vertebra, just to the right of the spinal canal and the 2nd cervical vertebra. This was a mushroomed, partially corroded, .22 caliber bullet which was initialed and placed in a specimen container for safekeeping. Thus, the bullet traveled from head to toe, but from left to right at an angle of approximately 15 degrees, and approximately 5 degrees from back to front.

Postmortem X-rays revealed a misshapen bullet in the 2nd cervical vertebra.


In addition to the skull and mandible and the small amount of soft tissue and cheesy material in each of the orbits, the following other bony structures were present: the sternum, the manubrium and the xiphoid of the sternum, 13 vertebrae (the 5th cervical was missing), two clavicles, two scapulae, the epiphyses of which were fused, 24 ribs, the sacrum, the pelvis which showed stage IV fusion of all major epiphyses, including the iliac crests. The symphysis pubis showed some fine bone infiltration of the dorsal portion of the symphyseal base. There was a well defined dorsal limiting margin. The upper and lower limits were not well defined. All right wrist bones, all right metacarpals and the proximal phalanx of the right thumb were present. The right femur measured 44.8 centimeters; left femur, 45 centimeters; left humerus, 30.6 centimeters; right humerus, 30.8 centimeters; left tibia, 38.2 centimeters; right tibia, 38.3 centimeters; a right fibula, 37.7 centimeters; the left ulna, 26.8 centimeters; the left radius, 23.6 centimeters. The distal epiphyses of both clavicles were fused. The medial epiphyses were not fused. The left clavicle showed evidence of injury and healing at its distal end. The very marked irregularities of the distal end suggested that there was a comminuted fracture involving at least the distal inch or so of the bone.

ESTIMATION OF AGE: The age estimated on the basis of the pubic symphysis was 22 to 24 years, although it is not inconsistent with a slightly younger age.

ESTIMATION OF STATURE: The height was estimated from the length of the femur. The femur had a physiologic height of 45.2 centimeters, calculated on the formula of Trotter and Gleaser. The height was estimated at 66-1/2 inches. Calculated on the formula Dupersius and Hatten, the height was 67 inches. The height of the decedent, therefore, was estimated at 65-1/2 to 67-1/2 inches.

DENTAL EXAMINATION

Universal System Charting: No fillings. Number 1, the upper right third molar is shaped like a paramolar. There is a diastema present between the upper right first bicuspid and cuspid, number 5 and 6, the upper right cuspid and laterals, number 6 and 7, the upper right and left centrals, 8 and 9, the upper left lateral and cuspid, 10 and 11, and the upper left and first bicuspid, 11 and 12. The upper left third molar, 16, is in its crypt. The lower left and lower right third molars are in their crypts. There are diastemas between the lower left cuspid and first bicuspid, 22 and 21, and the lower right cuspid and first bicuspid, 27 and 28. The jaw relationships are normal. Tooth 24 and 25 are in distal labial rotation.



Paul G. Stimson, D.D.S., M.S.

UNKNOWN #12

CASE 73 - 3350

- 5 -

August 22, 1973:

Repeat X-ray of long bones of lower extremity reveal a tiny radiopaque fragment at the epiphyseal end of the right lower femur. This was recovered and preserved.

Autopsy

INVESTIGATOR'S REPORT

Investigator: L. C. Kelly

~~View~~

Case No. 73-3350

Decedent: UNKNOWN #12 Race W Sex M Age

Address: UNKNOWN

Death: FOUND August 9, 1973 Approx. Time A.M.
 P.M.

Place of Death: UNKNOWN

Place of Inquest: Harris County Morgue and 4500 Silverbell Street, Houston,
Texas


Date and Time of Inquest: August 9, 1973 A.M.
 P.M.

Location, Position, and Surroundings of Body:

Clothing: The decedent was nude.

Information:

- 73-3349: Unknown #11-Found in the middle of Stall #11; Head to the west; at 4:00 p.m.
- 73-3350: Unknown #12-Found in the middle of Stall #11; Head to the east; at 4:00 p.m.
- 73-3353: Unknown #13-Found in the middle of Stall #11 and next to the front door; Head to the north; at approximately 6:00 p.m.
- 73-3354: Unknown #14-Found in the middle of Stall #11 and next to the front door; Head to the south; at approximately 6:00 p.m.
- 73-3355: Unknown #15-Found north end of Stall #11; Head to the east next to east side of Stall #11; at approximately 7:30 p.m.
- 73-3356: Unknown #16-Found six feet from center of north door; Head to the east; at approximately 8:00 p.m.
- 73-3357: Unknown #17-Found six feet from center of north door beside Unknown #16; Head to east; at approximately 8:00 p.m.


L. C. Kelly *NN*

(SEE COMPANION CASES: 73-3332, 73-3333, 73-3334, 73-3335, 73-3336, 73-3337, 73-3338, 73-3339, 73-3347, 73-3348, 73-3349, 73-3353, 73-3354, 73-3355, 73-3356, 73-3357)

Property: There was no property involved.

Transferred to Morgue by: William H. Posey Memorial Funeral Home, Inc., Galena Park, Texas
Bob Lee Funeral Home, Houston, Texas and Brookwood Funeral
Funeral Home Conducting Service: Home, Houston, Texas

JOSEPH A. JACHIMCZYK, M.D., J.D.

FORENSIC PATHOLOGIST
ATTORNEY AT LAW
CHIEF MEDICAL EXAMINER



(713) 796-9292



OFFICE OF THE MEDICAL EXAMINER OF HARRIS COUNTY
JOSEPH A. JACHIMCZYK FORENSIC CENTER
1885 OLD SPANISH TRAIL
HOUSTON, TEXAS 77054

SUPPLEMENTAL AND FINAL AUTOPSY REPORT

Case 73 - 3350

August 12, 1973

PATHOLOGICAL DIAGNOSES ON THE BODY

OF

UNKNOWN #12

Willard Karmon Branch, Jr. (7-3-85)


1. Gunshot wound of head.
2. Asphyxia due to gagging.
3. Old fracture of the skull.
4. Old healed injury of left clavicle.

OPINION

It is our opinion that the decedent, Unknown #12, came to his death as a result of a gunshot wound of the head, Homicide.

COMMENT

The presumptive identification is based upon 14 points of similarity and singularity.


Joseph A. Jachimczyk, M.D., J.D.

Chief Medical Examiner

(See Companion Cases 73-3332, 73-3333, 73-3334, 73-3335, 73-3336, 73-3337, 73-3338, 73-3339, 73-3347, 73-3348, 73-3349, 73-3353, 73-3354, 73-3355, 73-3356, 73-3357).

SUPPLEMENTAL AND FINAL REPORT (7-3-1985)

Case 73 - 3350

Unknown #12 - August 12, 1973

UNIDENTIFIED BODY ANTHROPOMETRY CHART

Willard Karmon Branch, Jr.

PHYSICAL ATTRIBUTE OF REMAINS

SUPPORTING INDICATOR

AGE: 22 to 24, but perhaps younger

AGE: 18 at disappearance
Date of birth 7-2-1954

SEX: Male

SEX: Male

RACE: Caucasian

RACE: Caucasian

HAIR: Dark brown

HAIR: Dark brown (Susan
McLemore selected #12)

HEIGHT: 5'5½" to 5'7½"

HEIGHT: 5'5" to 5'6"

Skull fracture, linear, right
parietal

Skull fracture, linear, right
parietal

Bone cyst, capitate, right
wrist

Bone cyst, capitate, right
wrist

Large central incisors

Large central incisors

Diastemas between teeth #9,
#10, #11

Diastemas between teeth #9,
#10, #11

Left lateral incisor
smaller than right

Left lateral incisor
smaller than right

No dental caries; no fillings,
no extractions

At age 15 family dentist stated
excellent dental health; no work
required; noted diastemas

Healed injury to left clavicle

Injured shoulder as a youngster

Tiny pellet recovered at lower
end of right femur

Shot by B.B. inside corner right
eye at age 4; pellet was migratory
in face

Body recovered August 9, 1973

Last seen November, 1972

POSTMORTEM EXAMINATION ON THE BODY OF

UNKNOWN #12

HISTORY: This body was one of seventeen bodies or skeletal remains recovered from Stall #11 at 4500 Silverbell Street, Houston, Texas, between 6:00 p.m., on August 8, 1973, and 8:00 p.m., on August 9, 1973. (See Companion Cases 73-3332, 73-3333, 73-3334, 73-3335, 73-3336, 73-3337, 73-3338, 73-3339, 73-3347, 73-3348, 73-3349, 73-3353, 73-3354, 73-3355, 73-3356, 73-3357).

AUTOPSY: The autopsy was performed by Chief Medical Examiner Joseph A. Jachimczyk, M.D., assisted by Paul Stimson, D.D.S., M.S., beginning at 11:30 a.m., on August 12, 1973, in the Harris County Morgue.

EXTERNAL APPEARANCE: The remains were submitted in a plastic sack and weighed a total of 43 pounds. They consisted of a deteriorating head with dark hair, measuring up to 5-1/2 inches in length and mostly bones and some cheesy-like material with very little soft tissue. There was a strand of parachute-type cord tied about the back sides of the decomposed wrists. A faint outline of the soft tissues of the right hand were still discernible, although the tissue was like cheese. Similar cord was tied around the tibias. It appeared that the wrists and legs were tied together, posteriorly. There was a small portion of black plastic material present with the remains. Over the head, there was a ligature mark depression at the level of the eyes. There was a terrycloth-type gag in the area of the mouth with adhesive tape around it. The facial tissues were not recognizable. There was a braided leather bracelet around the right wrist, consisting of three strands of leather braided and formed into a small knot at one end. There were no markings on it.

Elsewhere among the remnants, there was a plastic baggie with a knot on one end within which there was another plastic baggie in which there was a decomposing circumcised penis with some attached pubic hair at one end. The penis measured 10 centimeters in overall length. Within each of the other baggies, there was a collapsed testicle, one measuring up to 4-1/2 and the other up to 5 centimeters in greatest dimension. (It is likely these anatomic specimens do not belong to this body).

The skull had some adherent cheesy unrecognizable soft tissue with attached hairs and two sunken cheesy eyeballs within the orbits. The skull was of adult stature, a Caucasian male. The ectocranial suture lines showed no evidence of fusion. The three segments of the hyoid bone were present. The tip of the left cornu was

blackened. There was a gunshot hole in the calvarium in the left parietal bone at a point 5 inches above the left auditory meatus. This wound opening measured .25 inches in diameter. The bone edges were beveled inwardly. The wound admitted a probe which communicated to the 2nd cervical vertebra on the right, where a .22 caliber bullet was recovered in the 2nd cervical vertebra, just to the right of the spinal canal and the 2nd cervical vertebra. This was a mushroomed, partially corroded, .22 caliber bullet which was initialed and placed in a specimen container for safekeeping. Thus, the bullet traveled from head to toe, but from left to right at an angle of approximately 15 degrees, and approximately 5 degrees from back to front.

There was a linear, non-depressed fracture, beginning about 2-1/4 inches below the top of the head in the coronal suture extending down the parietal bone for approximately 2-1/2 inches to a point on the superior margin of the temporal bone on the right.

Postmortem X-rays revealed a misshapen bullet in the 2nd cervical vertebra. The X-ray of the right upper extremity revealed a cyst in the capitate member of the carpal bones.

In addition to the skull and mandible and the small amounts of soft tissue and cheesy material in each of the orbits, the following other bony structures were present: The sternum, the manubrium and the xiphoid of the sternum, 13 vertebrae (the 5th cervical was missing), two clavicles, two scapulae, the epiphyses of which were fused, 24 ribs, the sacrum, the pelvis which showed stage IV fusion of all major epiphyses, including the iliac crests. The symphysis pubis showed some fine bone infiltration of the dorsal portion of the symphyseal base. There was a well defined dorsal limiting margin. The upper and lower limits were not well defined. All right wrist bones, all right metacarpals and the proximal phalanx of the right thumb were present. The right femur measured 44.8 centimeters; left femur, 45 centimeters; left humerus, 30.6 centimeters; right humerus, 30.8 centimeters; left tibia, 38.2 centimeters; right tibia, 38.3 centimeters, a right fibula, 37.7 centimeters; the left ulna, 26.8 centimeters, the left radius, 23.6 centimeters. The distal epiphyses of both clavicles were fused. The medial epiphyses were not fused. The left clavicle showed evidence of injury and healing at its distal end. The very marked irregularities of the distal end suggested that there was a comminuted fracture involving at least the distal inch or so of the bone.

ESTIMATION OF AGE: The age estimated on the basis of the pubic symphysis was 22 to 24 years, although it is not inconsistent with a slightly younger age.

UNKNOWN #12

Case 73 - 3350

-5-

ESTIMATION OF STATURE: The height was estimated from the length of the femur. The femur had a physiologic height of 45.2 centimeters, calculated on the formula of Trotter and Gleaser. The height was estimated at 66-1/2 inches. Calculated on the formula Dupersius and Hatten, the height was 67 inches. The height of the decedent, therefore, was estimated at 65-1/2 to 67-1/2 inches.

August 22, 1973: Repeat X-ray of long bones of lower extremity reveal a tiny radiopaque fragment at the epiphyseal end of the right lower femur. This was recovered and preserved.

DENTAL EXAMINATION

Universal System Charting: No fillings. Number 1, the upper right third molar is shaped like a paramolar. There is a diastema present between the upper right first bicuspid and cuspid, numbers 5 and 6, the upper right cuspid and laterals, numbers 6 and 7, the upper right and left centrals, 8 and 9, the upper left lateral and cuspids, 10 and 11, and the upper left cuspid and first bicuspid, 11 and 12. The upper left third molar, 16, is in its crypt. The lower left and lower right third molars are in their crypts. There are diastemas between the lower left cuspid and first bicuspid, 22 and 21, and the lower right cuspid and first bicuspid, 27 and 28. The jaw relationships are normal. Teeth 24 and 25 are in distal labial rotation.

July 3, 1985

Joseph A. Jachimczyk, M.D., J.D.
Chief Medical Examiner of Harris County
1885 Old Spanish Trail
Houston, Texas

RE: Willard Karmon Branch, Jr.

Dear Dr. Jachimczyk:

On March 10, 1982, I first contacted your office in reference to my brother, above captioned, expressing the thought that he might be among those remaining unidentified of the "1973 Mass Murders". Since that time, in cooperation with your office, and in compliance with your request, I have furnished documents, pictures and personal information for use in comparisons of known similarities of my brother and of any unidentified remains of the "Mass Murder Victims".

I have been informed that a significant number of singularities and similarities exist between the remains of Medical Legal Number 73-3350 and the known physical, medical and personal histories of my brother. I realize that this is a presumptive identification. I accept and claim Medical Legal number 73-3350 as my brother, Willard Karmon Branch, Jr.

Sincerely,


Susan McLemore

BODY #	ML#	EST. HT.	RES. WT.	EST. AGE	FOUND	DATE	CAUSE OF DEATH
11	73-3349	69"-71 1/2"	44#	18-20	Shed	08/09/73	GSW of head
15	73-3355	70"-72 1/2"	56#	20-21	Shed	08/09/73	Strangulation
16	73-3356	63"-65"	?	18	Shed	08/09/73	Strangulation
22	73-3378	68"	75#	?	Sam Rayburn	DrPruitt	Strangulation

NOTE: Height estimate is +/- 2"

VIEW

Case No. 73-3350Decedent: UNKNOWN #12 Race W Sex M Age Address: UNKNOWNDeath: FOUND August 9, 1973 Approx. Time A.M.
 P.M.Place of Death: UNKNOWNPlace of Inquest: Harris County Morgue and 4500 Silverbell Street, Houston,
TexasDate and Time of Inquest: August 9, 1973 A.M.
 P.M.

Location, Position, and Surroundings of Body:

Clothing: The decedent was nude.

Information:

- 73-3349: Unknown #11-Found in the middle of Stall #11; Head to the west; at 4:00 p.m.
- 73-3350: Unknown #12-Found in the middle of Stall #11; Head to the east; at 4:00 p.m.
- 73-3353: Unknown #13-Found in the middle of Stall #11 and next to the front door; Head to the north; at approximately 6:00 p.m.
- 73-3354: Unknown #14-Found in the middle of Stall #11 and next to the front door; Head to the south; at approximately 6:00 p.m.
- 73-3355: Unknown #15-Found north end of Stall #11; Head to the east next to east side of Stall #11; at approximately 7:30 p.m.
- 73-3356: Unknown #16-Found six feet from center of north door; Head to the east; at approximately 8:00 p.m.
- 73-3357: Unknown #17-Found six feet from center of north door beside Unknown #16; Head to east; at approximately 8:00 p.m.

L. C. Kelly
L. C. Kelly *LCK*

(SEE COMPANION CASES: 73-3332, 73-3333, 73-3334, 73-3335, 73-3336, 73-3337, 73-3338, 73-3339, 73-3347, 73-3348, 73-3349, 73-3353, 73-3354, 73-3355, 73-3356, 73-3357)

Property: There was no property involved.

Transferred to Morgue by: William H. Posey Memorial Funeral Home, Inc., Galena Park, Texas
Bob Lee Funeral Home, Houston, Texas and Brookwood Funeral Home, Houston, Texas
Funeral Home Conducting Service:

Unk # 12

RECORD OF IDENTIFICATION PROCESSING
SKELETAL CHART

ML 73-3350

LAST NAME - FIRST NAME - MIDDLE INITIAL (or unknown number)

BLACK OUT PORTIONS NOT RECOVERED

GRADE SERVICE NUMBER

NAME OF CEMETERY, EVACUATION NUMBER, OR SEARCH AND RECOVERY NUMBER

PLOT ROW GRAVE

ESTIMATED AGE (Years) ESTIMATED HEIGHT
22-24 yrs 65 1/2 - 67 1/2 inches

SKELETAL MEASUREMENTS (Centimeters)

SKELETAL MEMBER	METHOD	RIGHT	LEFT
SKULL			
HUMERUS			
ULNA			
RADIUS			
FEMUR			
TIBIA			
FIBULA			

REMARKS OR STATEMENT OF ANTHROPOLOGIST (Continue on reverse if more space is required)

Healed fracture, distal end of left clavicle.

All bones present are shaded

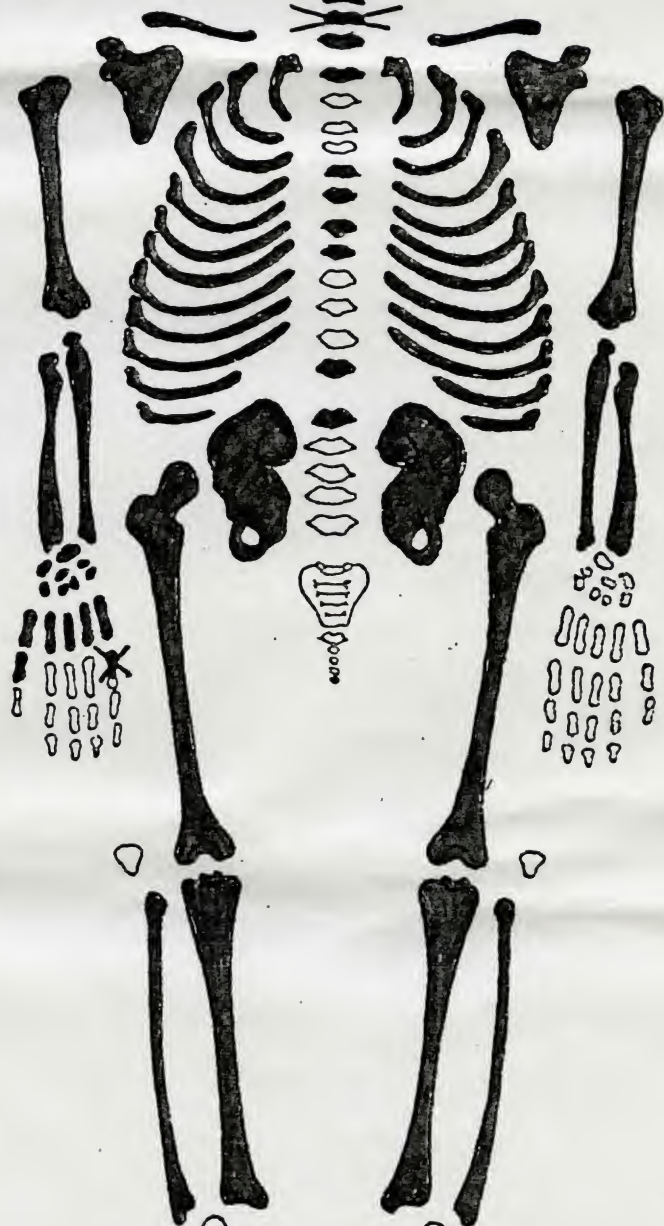THE PARTS PRESENT AS INDICATED ON THIS SKELETAL CHART REPRESENTS ONE AND THE SAME INDIVIDUAL

PHYSICAL ANTHROPOLOGIST (Name)

SIGNATURE



error - C-5 missing



SYMBOLS
MISSING
BURNED

FRACTURED
SHATTERED

STATE HIGHWAY PATROL

DENTAL CHART

Fill out all information in PENCIL

#12
 73-3350

Assigned identification number _____ Division Case Number _____
 Autopsy number _____ Picture Pouch Number _____
 Armed Forces Serial Number _____ Date of Exam. _____
 Social Security Number _____ Place of Exam. _____

IDENTIFICATION STATUS (CIRCLE ONE)

UNIDENTIFIED AT PRESENT TIME, PRESUMPTIVE BY EXCLUSION, HIGHLY PROBABLE, POSITIVE

Name of Person Identified	Age	Race	Sex
---------------------------	-----	------	-----

The above block is to be completed after all I.D. Procedures are exhausted.

CONFIRMED IDENTIFICATION OF BODY BY _____
Name of Examiner

Confirmed identification by means of (circle) X-ray comparison, Clinical conformation by previous dental records, Other _____

X-rays taken (circle one) None, Complete Mouth, Bite Wings, Other _____

Photographs taken (circle one) None, Color, Black & White, Other _____

Name, Address, and Telephone Number of Photographer

Location of the Body

Position of the Body

BEFORE PROCEEDING—READ PAGE 2 CAREFULLY AND FOLLOW ALL
 INSTRUCTIONS—HAVE A QUALIFIED ASSISTANT TO DO ALL RECORDING
 RECORD ALL INFORMATION IN PENCIL

Name, Address, and Telephone Number of the Examiner

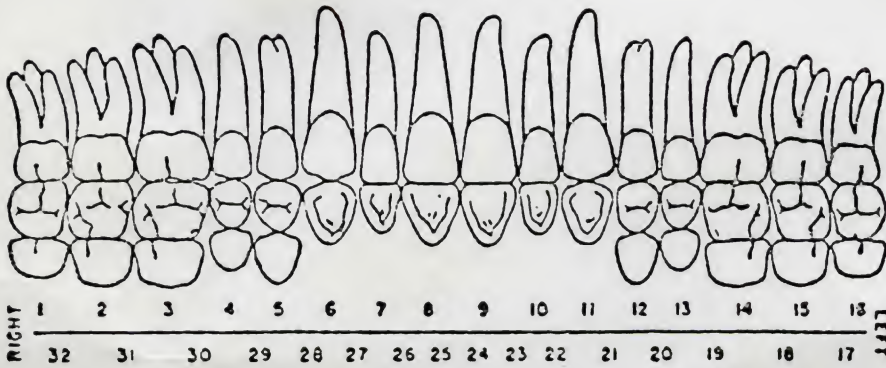
Name, Address, and Telephone Number of the Assistant

Signature of the examiner

Signature of the Assistant

MARK ALL EXISTING RESTORATIONS AND MISSING TEETH ON THIS CHART

Estimated Age _____
 Sex _____
 Race _____



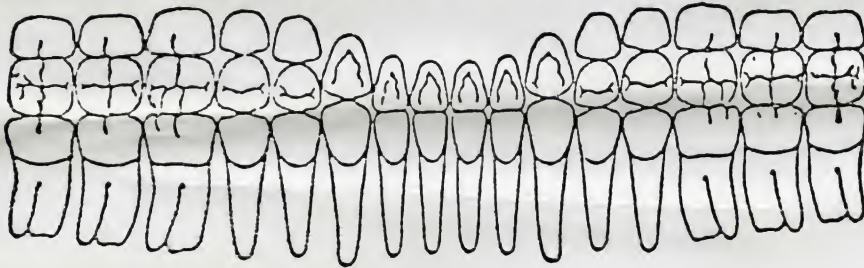Circle descriptive term

Prosthetic Appliances Present — Maxilla

Full Denture

Partial Denture

Fixed Bridge



Prosthetic Appliances Present — Mandible

Full Denture

Partial Denture

Fixed Bridge

Describe completely all Prosthetic Appliances or

Fixed Bridges: #24 + #25 Distal labial rotation

Stains on teeth

Slight

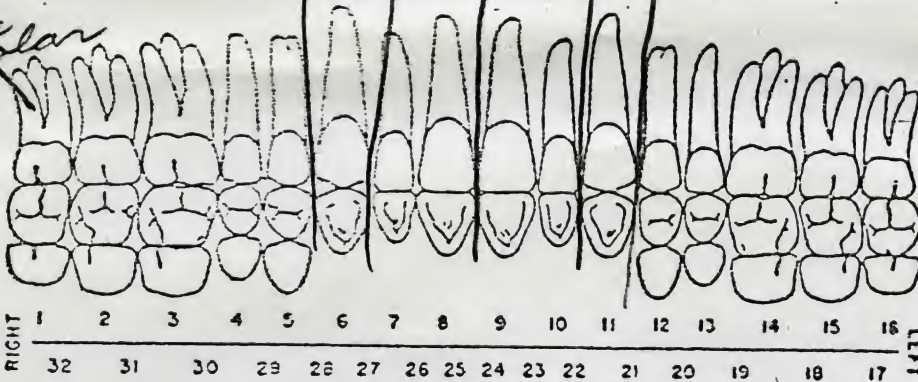
Moderate

Severe

Diastema

MARK ALL CARRIES AND MISSING TEETH ON THIS CHART

Outline all carries and 'X' out all missing teeth



Circle descriptive term

Jaw Relationship

Normal

Undershot

Overbite

Periodontal condition

Excellent

Average

Poor

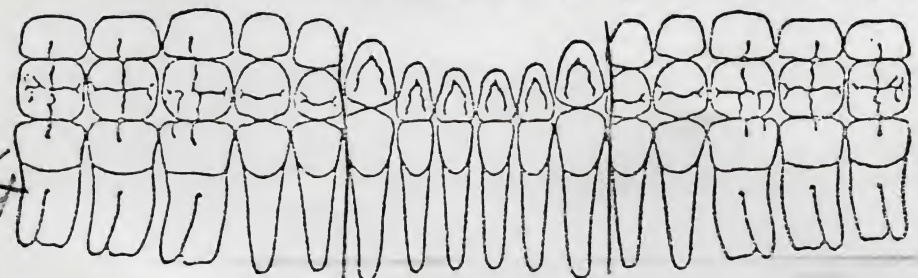
Gross Neglect

Calculus

Slight

Moderate

Severe



Branch

April 17, 1961

73-3350
#12

Helen G. Beddce, M. D.
5900 Lyons
Houston, Texas

Re: Willard K. Branch
507 Paschall
Houston, Texas

Dear Dr. Beddce:

Your courtesies in allowing me to see and examine this very nice child with you in Memorial Hospital are greatly appreciated.

The history as I obtained it from the parents at the time of my examination on April 12 is essentially that which had been previously related to you.

The neurological examination revealed the cranial nerves to be within normal limits. The child's neck was supple, the carotid pulses were normal and equal on the two sides, and there was no intracranial bruit. There was swelling, discoloration, and tenderness over the right parietal region of the scalp. The deep tendon reflexes were physiological. I was not able to demonstrate any motor weakness or sensory deficit in any of his limbs.

X-rays of the skull showed a 3 inch linear fracture without displacement, extending downwards from the parietal region on the right.

In the hospital on conservative management, this child improved rapidly and was discharged after 3 days. I hope he will return to your office for re-examination in about 10 days so that his clinical course can be followed.

Yours very truly,

Thomas H. McGuire, M. D.

THM/mj

Name: FRANK WOODS
 Address: 807 PASCHELL
 Age: 6
 Tel: No. 3456

Occupation: Clerk
 (S. M. W. D.)

C. C. Occident
 History of Present Illness:

Fell from a tall set house. I then
 lay on my back for several hours.
 My arm probably not unscathed.
 The pain complained of gradually
 became heavier & remained several hours.
 Since then C. C. by Dr. Hedden
 was placed in the hospital.

CRANIAL NERVES

- Optic
- Olfactory
- Otic Nerve
- Facial Nerve
- Vestibular
- Auditory
- Stomach and Intestine
- Vagus Nerve
- Pharyngeal
- Taste
- Smell

REFLEXES LEFT RIGHT

- Cervical
- Biceps
- Triceps
- Abdominal
- Patellar
- Achilles
- Babinski
- Hoffman
- Jelicic Clonus

MOTOR STATUS:

- Strength
- Tone
- Coordination
- F N Test
- H R Test
- Gait

SENSORY

- Touch
- Pain
- Position
- Vibration
- Strognoods
- S. L. H. O.
- Patellar
- Tenderness Disc

VASCULAR:

- B. P.

Place of Exam.: ASHLEY
 Referred by: Dr. B. B. B. B.


With simple
 could give the
 as that best.

Shell of - rays, crossed a 3 in
 lower portion & displaced
 relatively downward from parietal
 region on ft.

DIAGNOSIS: Shell fracture
 Displaced comminuted
 700g. toward - elbow -
 Treatment: 700g. observation

THOMAS H. MCGUIRE, M.D., P.A.

1213 HERMANN DRIVE - SUITE 640
HOUSTON, TEXAS 77004



Rec'd 5-3-83

WILLIAM KARMEN BRANCH

~~73-12~~
73-12

Mr. Cecil Wingo, Chief Medical Examiner
Harris County Medical Office
1502 Outer Belt
Houston, Tx 77036

FOR OFFICE USE ONLY

July 3, 1985

Case 73 - 3350

Investigator Cecil Wingo

Willard Karmon Branch, Jr., date of birth, July 2, 1954, Unknown number 12. Mother is Mrs. Bonnie Clark, P.O. Box 448, Beckville, Texas 75631. Sister is Susan McLemore.

The remains of Medical Legal Case Number 73-3350 are presumptively identified as being those of Willard Karmon Branch, Jr. This identification is based upon both singularities and similarities that have been determined by careful comparison of known anatomical attributes of the remains of Medical Legal Number 73-3350 and known anatomical attributes of Willard Karmon Branch, Jr.

Willard Karmon Branch, Jr., was last seen in November, 1972, in Mt. Pleasant, Texas, by his aunt, whom he was visiting, when she took both Branch and an unidentified white male from her home to the highway in order that they might hitchhike to Houston. According to a report filed by Branch's father, Willard Karmon Branch, Sr., (deceased 3-3-80), Branch was 5' 5" to 5' 6" tall and weighed approximately 130 pounds. His hair was dark brown. In addition, the report stated that Branch had been a patient of Dr. H. Beddoe and Dr. T. H. McGuire at Memorial Hospital, where he was treated for a fractured skull. The year of the injury was 1961.

Subsequently and on March 10, 1982, Branch's sister, Susan McLemore, contacted this office in reference to her brother. In this interim of the initial contact and to this date, Susan McLemore has assisted this office by locating some medical records and by providing photographs and a personal history of Branch.

The evidentiary items obtained relative to Branch included an X-ray of the left hand and an X-ray of the right hand, a copy of a letter dated April 17, 1961, addressed to Helen G. Beddoe, M.D., from Thomas H. McGuire, M.D., with the caption, RE: Willard K. Branch, 807 Paschall, Houston, Texas. The letter contained the following paragraph; "X-rays of the skull showed a 3 inch linear fracture without displacement, extending downwards from the parietal region on the right", and a facial photograph of Branch at about 12 or 13. This photograph was important because it would allow for a comparison of the upper front dentition of Branch with dentition of Case 73-3350.

Information of narrative character indicated that Branch had "Fairly high cheek bones, two upper front teeth were larger, upper left medial incisor sharp and smaller than other." It was also said that Branch had suffered an injury to a shoulder as a youngster.

On September 14, 1983, Susan McLemore was shown two boards on which were mounted 23 locks of hair from the companion cases to 73-3350. All but 8 locks of hair were eliminated because of obvious dissimilarities. The locks examined were numbers 12, 18, 19, 20, 21, 23, 24 and 25. Locks numbers 18, 19, 20, 21 and 28 were determined by McLemore to be too light in color, number 24 was too curly. Numbers 12 and 25 were similar. McLemore elected number 12 as the first choice and number 25 as the second choice. Number 25 belonged to an individual previously identified as Johnny Ray Delone, Number 12 is the lock from this case, #73-3350.

The remains of 73-3350 were found in Stall #11 at 4500 Silverbell, Houston, Texas, between 6:00 p.m., on August 8, 1973, and 8:00 p.m., on August 9, 1973. These skeletal remains were found along with the remains of sixteen other bodies. Those medical legal numbers are referred to in the autopsy report. Characteristics with potential for use in identification excerpted from the autopsy report: "dark hair, measuring up to 5-1/2 inches in length...., the left clavicle showed evidence of injury and healing at its distal end...., the age estimated on the basis of the pubis symphysis was 22 to 24 years, although it is not inconsistent with a slightly younger age..., the height of the decedent was estimated at 65-1/2 to 67-1/2 inches." Excerpted from the report of the dental examination is the sentence "There is a diastema present between...the upper left lateral and cuspid, 10 and 11, and the upper left cuspid and first bicuspid, 11 and 12." Excerpted from the autopsy report "There was a linear, non-depressed fracture, beginning about 2-1/4 inches below the top of the head in the coronal suture extending down the parietal for approximately 2-1/2 inches to a point on the superior margin of the right temporal bone."

X-rays were made of the skeletal remains upon receipt. The remains were incomplete but that which was not recovered represented only some of the small bones of the hands and feet and vertebrae. Included in the remains of the right extremity were the carpals of the right hand.

Identifiers of singular character used in determination were:

1. Skull
2. X-rays of right upper extremity, both from 73-3350
3. X-ray of the right hand of Willard Karmon Branch, Jr
4. Letter from Dr. McGuire to Dr. Beddoe in which a skull fracture of the head of Branch was described.
5. Clavicle injury described in the autopsy report.
6. Familial recall of a shoulder injured stated by Susan McLemore
7. Familial recall of outstanding dental characteristics of Branch
8. Dental charting and photographs of the teeth of 73-3350
9. Photograph of Branch taken at age 12 or 13

The skull fracture described in the autopsy report of 73-3350 is very clearly described in the letter from Dr. McGuire to Dr. Beddoe dated April 17, 1961.

A bone cyst was found to exist in the capitate member of the carpal bones of the right upper extremity when this X-ray of 73-3350 was examined. This same bone cyst is present in the X-ray of the right hand of Branch.

Susan McLemore recalled that her brother had suffered a shoulder injury. The autopsy report of 73-3350 described a healed injury to the left clavicle.

Family members described Branch as having large upper central incisors and a lateral incisor on the left which was smaller than the other. The photograph of Branch demonstrates this description in addition to displaying diastemas in the upper arch. Examination of the upper dental arch of 73-3350 clearly supports the size relationships of the teeth and the diastemas. The teeth visible in the photographs are numbers (Universal Chart) 7, 8, 9 and 10. The upper dental arch of 73-3350 demonstrates the diastemas present between the left central incisor, number 9 and the left lateral, number 10, and the left lateral, number 10, and the cuspid, number 11.

Identifiers of similar character used in determinations were:

1. Known age, race, height, weight, sex and hair color of Willard Karmon Branch, Jr.
2. Findings of autopsy of age, race, height, sex and hair color.
3. The selection of hair specimen by Susan McLemore.

The known personal characteristics of Branch at time of disappearance were as follows: age 18, height 5'5" to 5'6", weight 130 pounds, race white, sex male, hair color dark brown. The estimates at autopsy report of 73-3350 of these same characteristics were: age 22 to 24, but not inconsistent with a slightly younger age, height 5'5½" to 5'7½", weight was not estimated, the race was Caucasian, the sex was male.

According to McLemore, Willard Karmon Branch, Jr., was shot in the inside corner of the right eye with a B.B. gun. The pellet penetrated and remained in the tissue. Branch's age at that time was 4 years. The pellet was watched carefully because it subsequently migrated downward into the cheek.

The family dentist evaluated Branch at age 15 and found his dentistry to be excellent and required no work. He noted the diastemas.

Investigators Report
Continuation/Supplement

Date: 6-26-85

Investigator WINGO

Time: _____

office use only

Case No. 73-3350

SUSAN McLEMORE WAS CONTACTED BY TELEPHONE IN ORDER TO DETERMINE
WHETHER McLEMORE WOULD CONTACT HER MOTHER REFERENCE THE
IDENTIFICATION OF HER BROTHER, THIS DEC., OR WOULD SHE RATHER
THIS OFFICE MAKE THE CONTACT. McLEMORE STATED SHE HAD BEEN IN
CONTACT WITH HER MOTHER BUT THAT HER MOTHER PREFERRED NOT TO
BE PRESENT DURING THE IDENTIFICATION

To Dr. J.

Date 12-2-87 Time 8:10 a.m.

12-4-87 8:30 am

WHILE YOU WERE OUT

M. Ms. SUSAN Mc Lemore

of Sister of decedent

Phone ^{wk:} 953-6679 or 866-2344 ^{pager}

Area Code

Number

Extension

TELEPHONED	<input checked="" type="checkbox"/>	PLEASE CALL	<input checked="" type="checkbox"/>
CALLED TO SEE YOU	<input type="checkbox"/>	WILL CALL AGAIN	<input type="checkbox"/>
WANTS TO SEE YOU	<input type="checkbox"/>	URGENT	<input type="checkbox"/>

RETURNED YOUR CALL

73-3350

Message Re: Mr. Willard Branch, Jr.

(Mass murder Victims -
subsequently identified in 1985)
She advised decedent's mother
is going to get a court order
today to have body exhumed
if her call is not returned. ^{Operator} ~~They~~ ^{Mother}



WILSON BUSINESS PRODUCTS
 6869 Katy Road
 Houston, Texas 77024
 (713) 868-6566

Reorder:
 WIL23.000

-EVID-

is
are not convinced that
is him, and they would like
to re clarify some things
with you.

She also advised
"Dr. Wing" has been
avoiding her calls, and that
they will go to the press
if we keep avoiding them.

953-6478
6479
re - apt. home: 466-7155
w/ Dr. J. C.W.
to her & her mother

12-8-57
Cecil spoke with
her & will follow
up - or

To O/GA

Date 12/2/87 Time 4:50pm

WHILE YOU WERE OUT

M. SUSAN Mc Lemore

of _____

Phone _____

Area Code

Number

Extension

TELEPHONED	<input checked="" type="checkbox"/>	PLEASE CALL	
CALLED TO SEE YOU	<input type="checkbox"/>	WILL CALL AGAIN	
WANTS TO SEE YOU	<input type="checkbox"/>	URGENT	

RETURNED YOUR CALL

Message Said to tell you

She will be out of town on
Thursday, 12/3/87, and asked
if you would call her mother.

Mrs. Bonnie Clark

214-938-1856

Mrs. McLemore will call you back

Operator



WILSON BUSINESS PRODUCTS
6869 Katy Road
Houston, Texas 77024
(713) 868-6566

Friday.
Reorder: WIL23009
Ruby

12-84

Mr. Wings,

Enclosed is the picture showing the leather band that Lusty always wore. I hope it helps you. By the way, in case I never mentioned it Lusty's right ear was pierced. He wore a variety of gold earrings so I can't tell you which one he was wearing the day he left. I hope you had a nice Christmas. Let me hear from you soon.

Susan McLemore

rec'd 1-2-85